



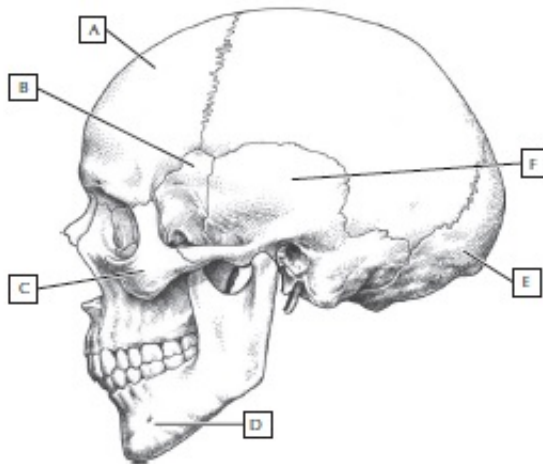
0-WEB.ru

[Clinicalanatomyreviewsnelpdfdownload](#)

REVIEW QUESTIONS

1. Color the bones of the human skull indicated by the letters on the image:

- Frontal bone (color green)
- Sphenoidal bone (color yellow)
- Zygomatic bone (color brown)
- Mandible (color blue)
- Occipital bone (color red)
- Temporal bone (color orange)



2. What is the name of the four teeth at the front of each jaw? _____
3. The arch of a thoracic vertebra is formed by which two paired elements? _____
4. What artery passes through the foramen transversarium of the cervical vertebra? _____
5. Which three bones form the pectoral girdle and arm of the upper limb? _____
6. Which carpal bone articulates with the metacarpal of the thumb? _____
7. What are the three bones that fuse to form the bony pelvis? _____
8. Most fractures of the femur involve which portion of the bone? _____
9. Which ligament of the knee, if torn, will result in excessive extension at the joint? _____
10. Which pair(s) of ribs is/are considered "floating ribs?" _____



0-WEB.ru

624b518f5d